SYSTEMIC SCLEROSIS

A rare, progressive, immune-mediated disease

SYSTEMIC SCLEROSIS

A rare, progressive, immune-mediated disease

Reported incidence between **3.7 and 23 cases per million**

Reported prevalence of **2 individuals per 10,000**

Strong sex bias with a ratio of **3:1 more women than men** affected

Mortality rate is greater than in any other rheumatic disease

Barnes J, Mayes MD. *Curr Opin Rheumatol*. 2012;24(2):165-170.
Denton CP, Khanna D. *Lancet*. 2017. doi:10.1016/S0140-6736(17)30933-9.
Oliver JE, Silman AJ. *Arthritis Res Ther*. 2009;11(5):252.
Pellar PE, Pope JE. S*emin Arthritis Rheum*. 2017;46(6):767-774.

SYSTEMIC SCLEROSIS CLINICAL SUBTYPES

A rare, progressive, immune-mediated disease

Without skin involvement
(<5% patients)

With skin involvement
(≥95% patients)

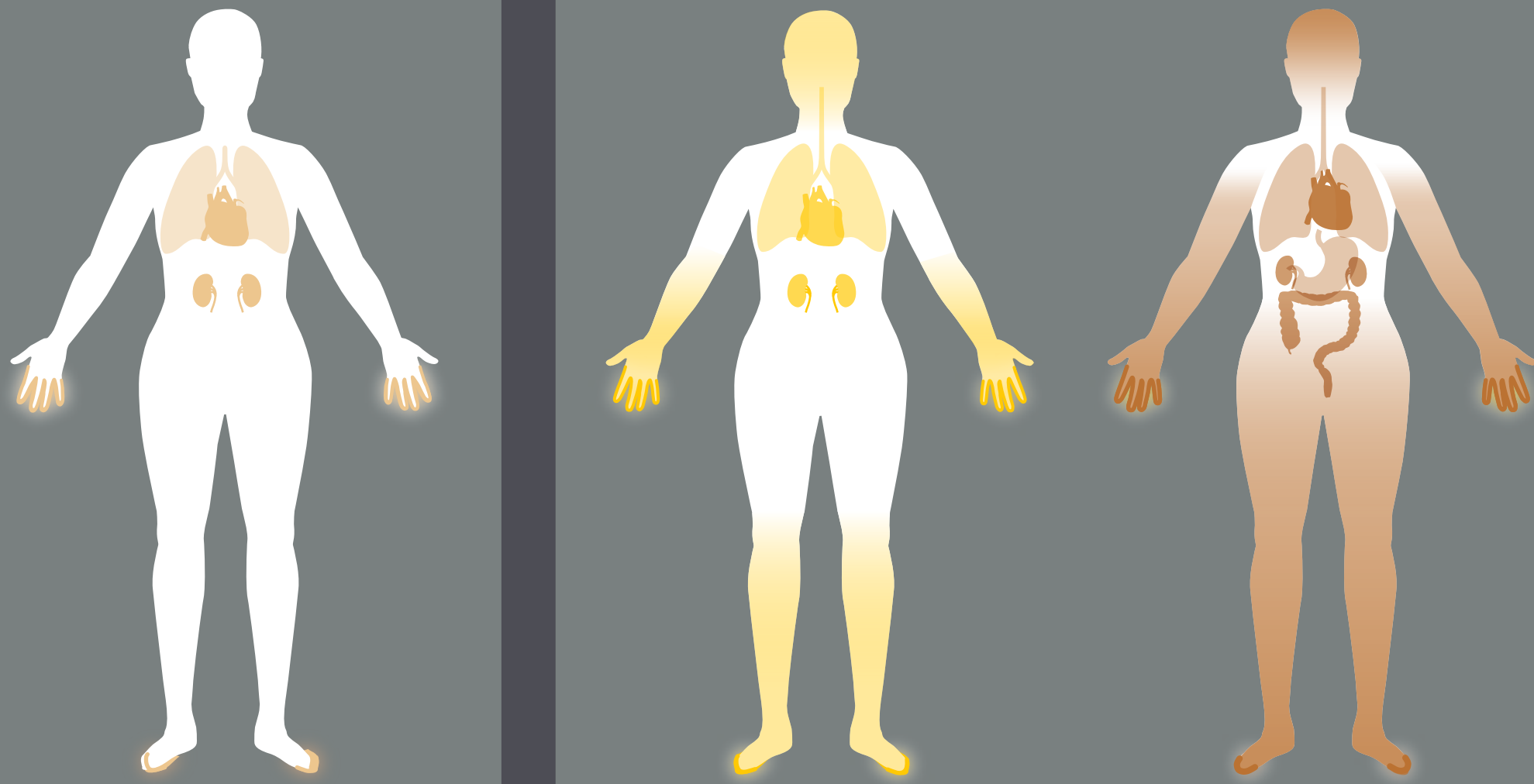

SYSTEMIC SCLEROSIS SINE SCLERODERMA

LIMITED CUTANEOUS SYSTEMIC SCLEROSIS

DIFFUSE CUTANEOUS SYSTEMIC SCLEROSIS

SYSTEMIC SCLEROSIS OVERLAP SYNDROME

Manifestations of 1 of the 3 subtypes, with clinical and investigational features of another rheumatic disease

Denton CP, Khanna D. *Lancet*. 2017. doi:10.1016/S0140-6736(17)30933-9.

SYSTEMIC SCLEROSIS SINE SCLERODERMA

An infrequent subtype with internal organ but no skin involvement

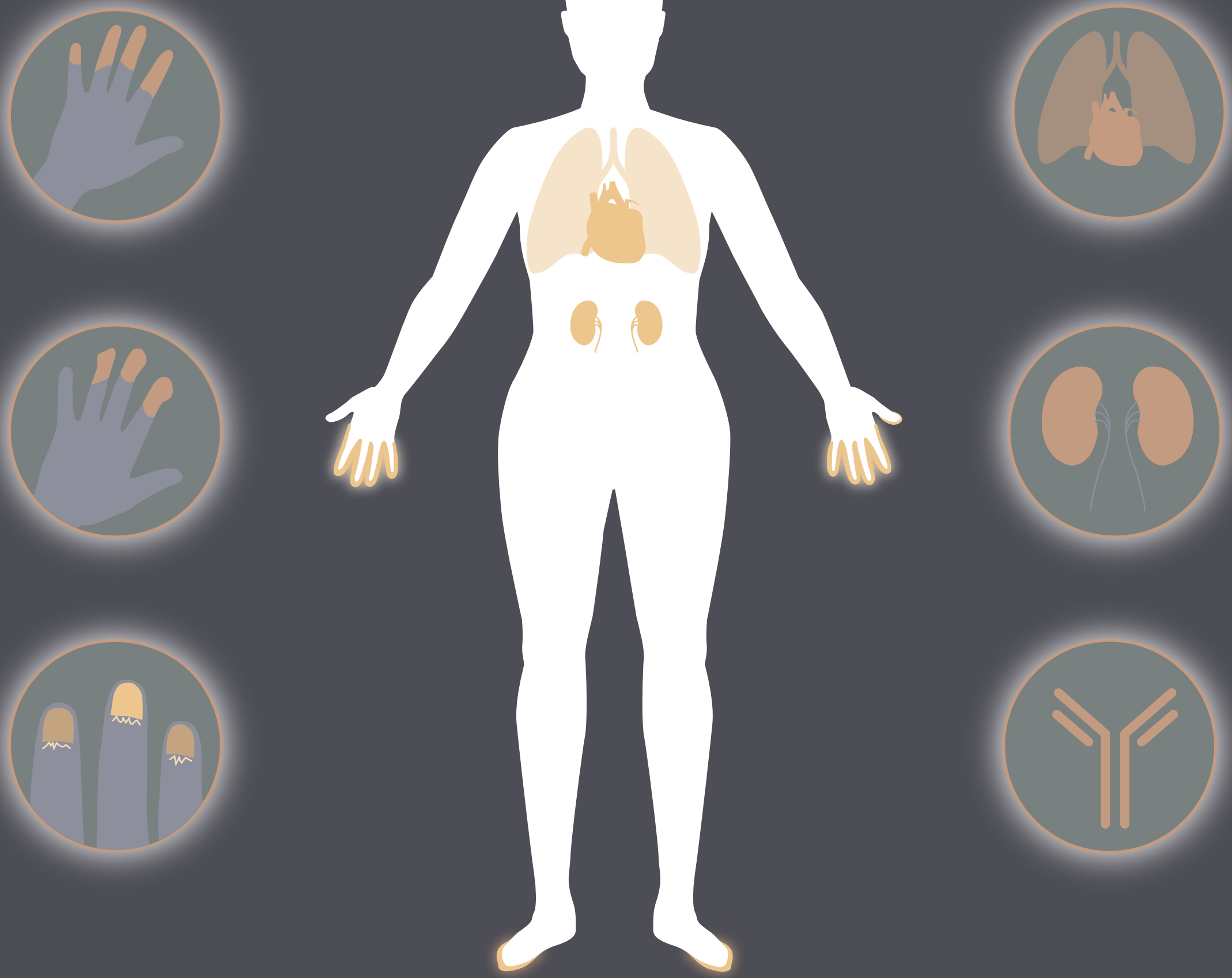

These images depict examples of some of the manifestations observed in patients with systemic sclerosis. This is for educational purposes only and should not be used as the basis for systematic assessment and follow-up. Patient clinical presentations may vary.

SYSTEMIC SCLEROSIS SINE SCLERODERMA

An infrequent subtype with internal organ but no skin involvement

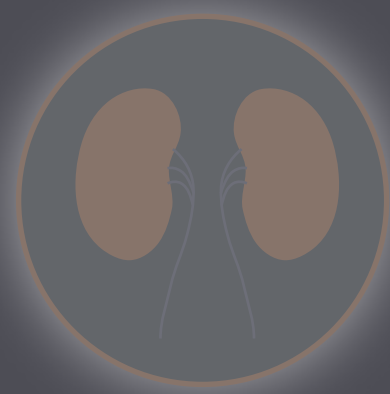

Clinical presentation

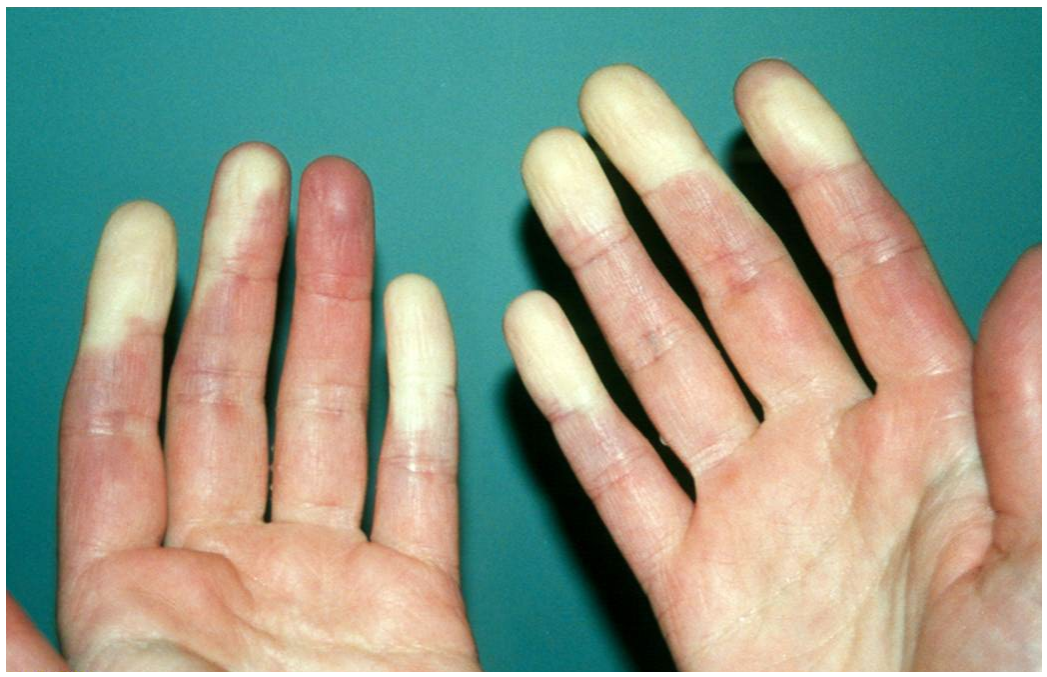

Raynaud's phenomenon is a common feature of systemic sclerosis sine scleroderma.

Denton CP, Khanna D. *Lancet*. 2017. doi:10.1016/S0140-6736(17)30933-9.

These images depict examples of some of the manifestations observed in patients with systemic sclerosis. This is for educational purposes only and should not be used as the basis for systematic assessment and follow-up. Patient clinical presentations may vary.

SYSTEMIC SCLEROSIS SINE SCLERODERMA

An infrequent subtype with internal organ but no skin involvement

Clinical presentation

Digital ulcers are common.

Denton CP, Khanna D. *Lancet*. 2017. doi:10.1016/S0140-6736(17)30933-9.

These images depict examples of some of the manifestations observed in patients with systemic sclerosis. This is for educational purposes only and should not be used as the basis for systematic assessment and follow-up. Patient clinical presentations may vary.

SYSTEMIC SCLEROSIS SINE SCLERODERMA

An infrequent subtype with internal organ but no skin involvement

Clinical presentation

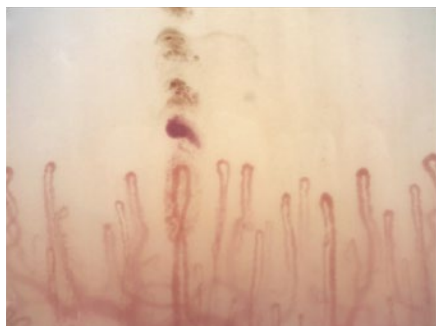

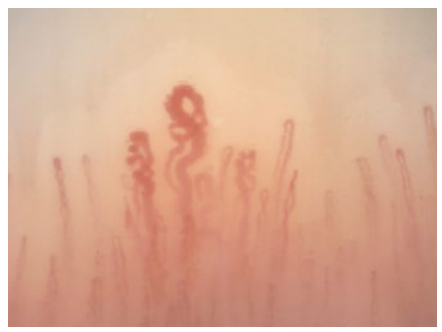

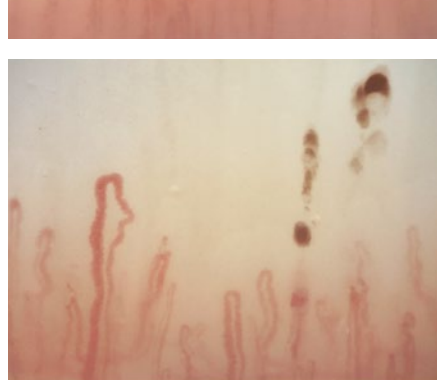

Capillary abnormalities typical of systemic sclerosis, observed in the cuticles.

Denton CP, Khanna D. *Lancet*. 2017. doi:10.1016/S0140-6736(17)30933-9.

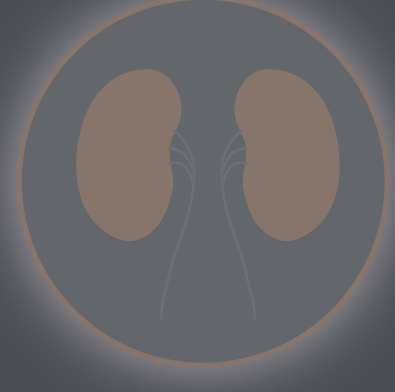

These images depict examples of some of the manifestations observed in patients with systemic sclerosis. This is for educational purposes only and should not be used as the basis for systematic assessment and follow-up. Patient clinical presentations may vary.

SYSTEMIC SCLEROSIS SINE SCLERODERMA

An infrequent subtype with internal organ but no skin involvement

Clinical presentation

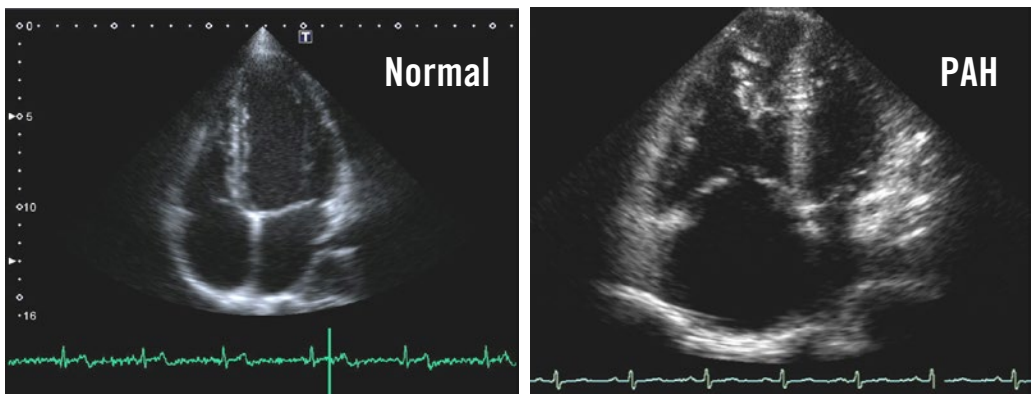

Images courtesy of Dr Luke Howard, DPhil, FRCP.

Pulmonary arterial hypertension (PAH) is frequent.

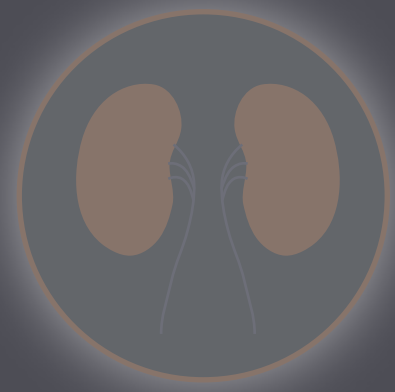

Denton CP, Khanna D. *Lancet*. 2017. doi:10.1016/S0140-6736(17)30933-9.

These images depict examples of some of the manifestations observed in patients with systemic sclerosis. This is for educational purposes only and should not be used as the basis for systematic assessment and follow-up. Patient clinical presentations may vary.

SYSTEMIC SCLEROSIS SINE SCLERODERMA

An infrequent subtype with internal organ but no skin involvement

Clinical presentation

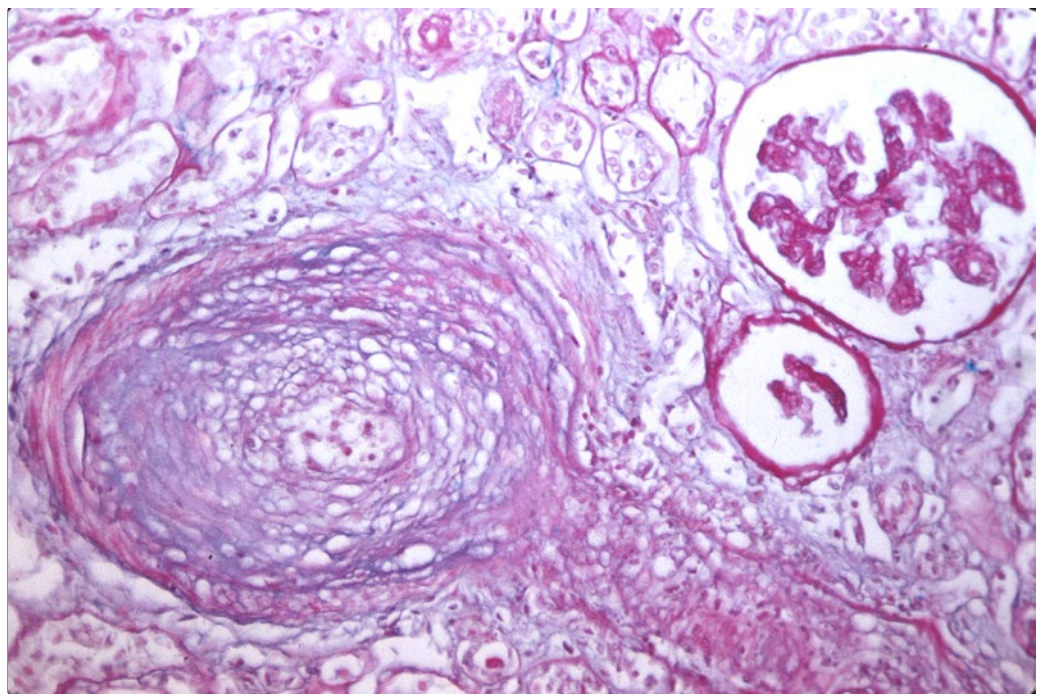

Thrombotic microangiopathy in the kidney can lead to renal crisis.

Denton CP, Khanna D. *Lancet*. 2017. doi:10.1016/S0140-6736(17)30933-9.

These images depict examples of some of the manifestations observed in patients with systemic sclerosis. This is for educational purposes only and should not be used as the basis for systematic assessment and follow-up. Patient clinical presentations may vary.

SYSTEMIC SCLEROSIS SINE SCLERODERMA

An infrequent subtype with internal organ but no skin involvement

Autoantibody profile

Anticentromere autoantibodies are associated with pulmonary arterial hypertension. Anti-Scl-70 (anti-DNA-topoisomerase I) autoantibodies are associated with digital ulcers.

Denton CP, Khanna D. *Lancet*. 2017. doi:10.1016/S0140-6736(17)30933-9.

These images depict examples of some of the manifestations observed in patients with systemic sclerosis. This is for educational purposes only and should not be used as the basis for systematic assessment and follow-up. Patient clinical presentations may vary.

LIMITED CUTANEOUS SYSTEMIC SCLEROSIS

A subtype with restricted skin but major internal organ involvement

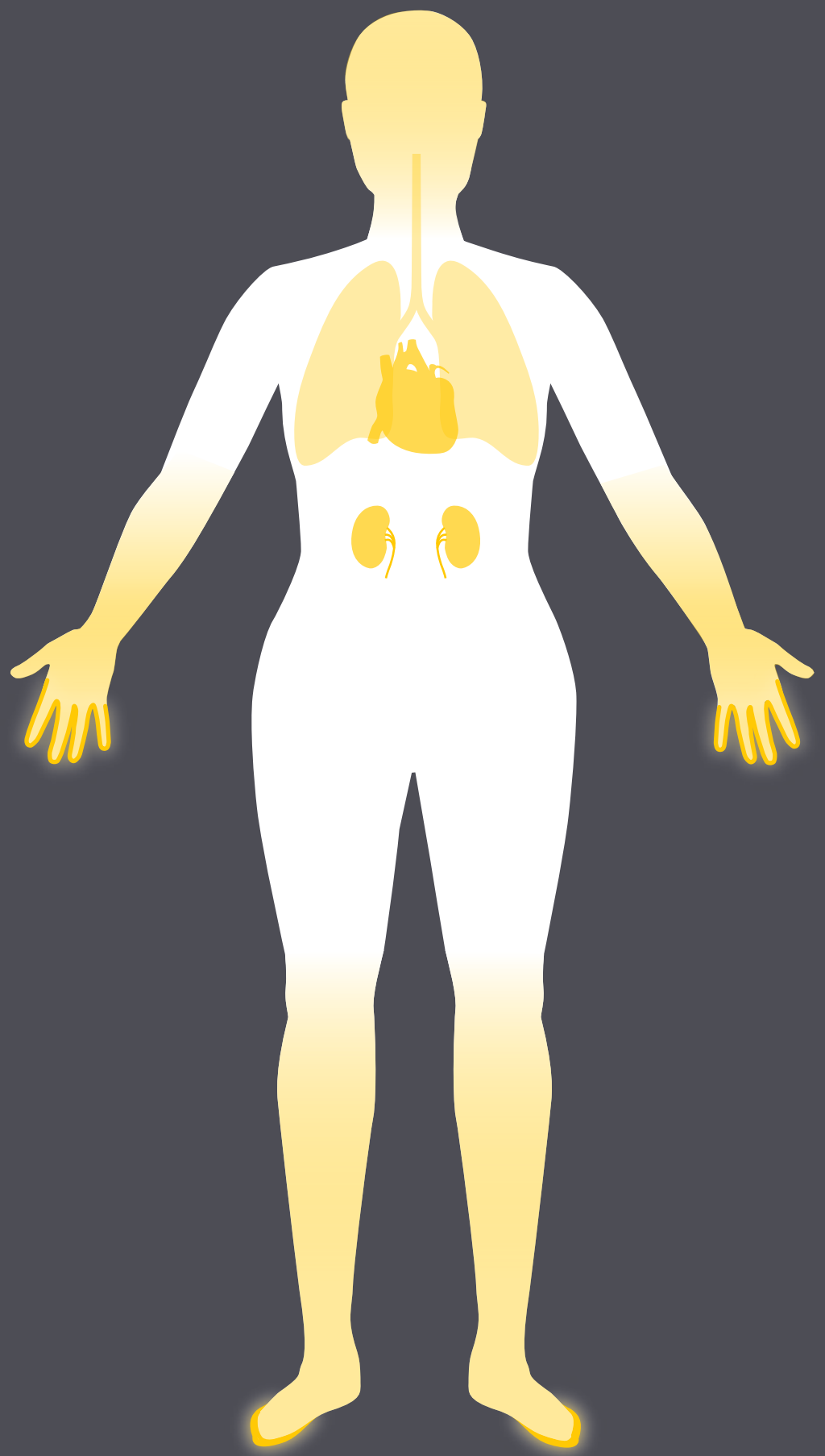

These images depict examples of some of the manifestations observed in patients with systemic sclerosis. This is for educational purposes only and should not be used as the basis for systematic assessment and follow-up. Patient clinical presentations may vary.

LIMITED CUTANEOUS SYSTEMIC SCLEROSIS

A subtype with restricted skin but major internal organ involvement

Clinical presentation

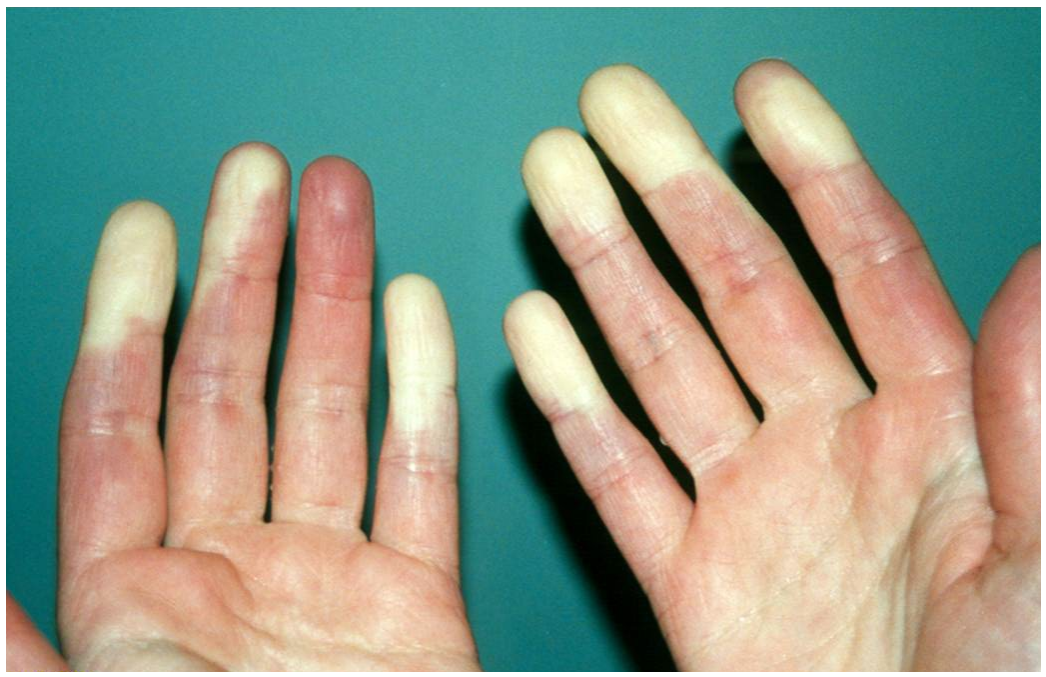

Typically there is long history of Raynaud's phenomenon.

Denton CP, Khanna D. *Lancet*. 2017. doi:10.1016/S0140-6736(17)30933-9.

These images depict examples of some of the manifestations observed in patients with systemic sclerosis. This is for educational purposes only and should not be used as the basis for systematic assessment and follow-up. Patient clinical presentations may vary.

LIMITED CUTANEOUS SYSTEMIC SCLEROSIS

A subtype with restricted skin but major internal organ involvement

Clinical presentation

Sclerodactyly occurs late and is limited to fingers and toes. Extensive calcinosis cutis may occur.

Denton CP, Khanna D. *Lancet*. 2017. doi:10.1016/S0140-6736(17)30933-9.
Pattanaik D, et al. *Front Immunol*. 2015;6:272. doi:10.3389/fimmu.2015.00272.

These images depict examples of some of the manifestations observed in patients with systemic sclerosis. This is for educational purposes only and should not be used as the basis for systematic assessment and follow-up. Patient clinical presentations may vary.

LIMITED CUTANEOUS SYSTEMIC SCLEROSIS

A subtype with restricted skin but major internal organ involvement

Clinical presentation

Facial and mucosal membrane telangiectasias are a common clinical presentation.

Chu CH, et al. *Clin Oral Investig.* 2011;15(6):931-939.
Denton CP, Khanna D. *Lancet*. 2017. doi:10.1016/S0140-6736(17)30933-9.
Pattanaik D, et al. *Front Immunol*. 2015;6:272. doi:10.3389/fimmu.2015.00272.

These images depict examples of some of the manifestations observed in patients with systemic sclerosis. This is for educational purposes only and should not be used as the basis for systematic assessment and follow-up. Patient clinical presentations may vary.

LIMITED CUTANEOUS SYSTEMIC SCLEROSIS

A subtype with restricted skin but major internal organ involvement

Clinical presentation

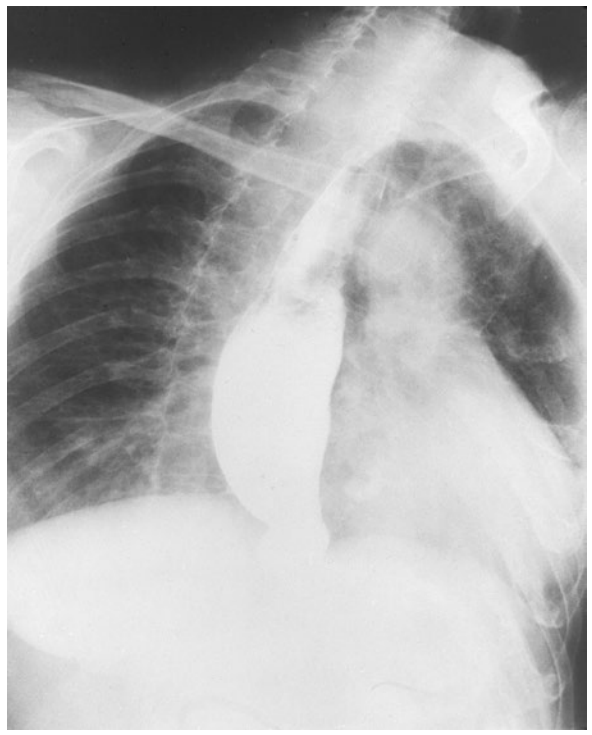

Esophageal dysmotility, which results in gastroesophageal reflux, is a frequent gastrointestinal feature.

Denton CP, Khanna D. *Lancet*. 2017. doi:10.1016/S0140-6736(17)30933-9.
Pattanaik D, et al. *Front Immunol*. 2015;6:272. doi:10.3389/fimmu.2015.00272.

These images depict examples of some of the manifestations observed in patients with systemic sclerosis. This is for educational purposes only and should not be used as the basis for systematic assessment and follow-up. Patient clinical presentations may vary.

LIMITED CUTANEOUS SYSTEMIC SCLEROSIS

A subtype with restricted skin but major internal organ involvement

Clinical presentation

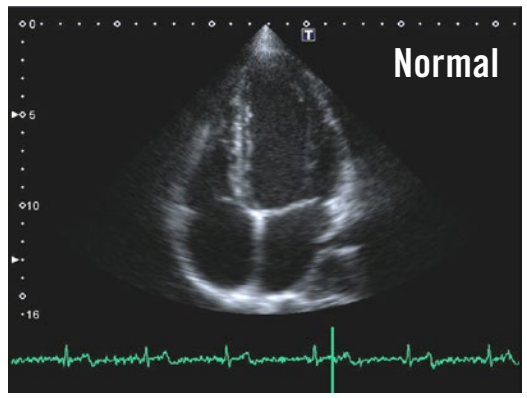

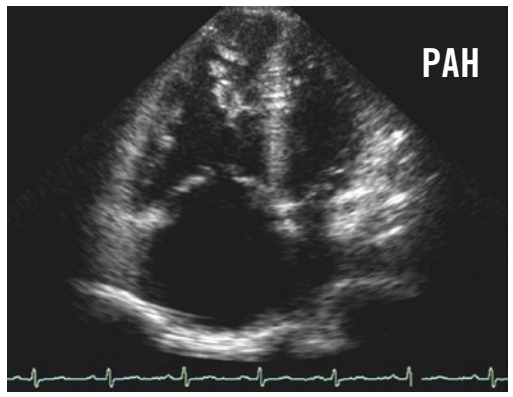

Images courtesy of Dr Luke Howard, DPhil, FRCP.

Severe pulmonary arterial hypertension (PAH) is frequent.

Denton CP, Khanna D. *Lancet*. 2017. doi:10.1016/S0140-6736(17)30933-9.
Pattanaik D, et al. *Front Immunol*. 2015;6:272. doi:10.3389/fimmu.2015.00272.

These images depict examples of some of the manifestations observed in patients with systemic sclerosis. This is for educational purposes only and should not be used as the basis for systematic assessment and follow-up. Patient clinical presentations may vary.

LIMITED CUTANEOUS SYSTEMIC SCLEROSIS

A subtype with restricted skin but major internal organ involvement

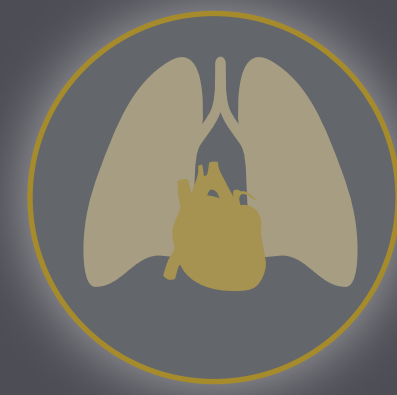



Autoantibody profile

Anticentromere autoantibodies are detected in 70%–80% of patients and are associated with a high risk of pulmonary hypertension. Anti-Th/To autoantibodies have also been detected in a subset of patients.

Gabrielli A, et al. *N Engl J Med*. 2009;360(19):1989-2003.

These images depict examples of some of the manifestations observed in patients with systemic sclerosis. This is for educational purposes only and should not be used as the basis for systematic assessment and follow-up. Patient clinical presentations may vary.

DIFFUSE CUTANEOUS SYSTEMIC SCLEROSIS

A subtype with extensive internal organ and skin involvement

These images depict examples of some of the manifestations observed in patients with systemic sclerosis. This is for educational purposes only and should not be used as the basis for systematic assessment and follow-up. Patient clinical presentations may vary.

DIFFUSE CUTANEOUS SYSTEMIC SCLEROSIS

A subtype with extensive internal organ and skin involvement

Clinical presentation

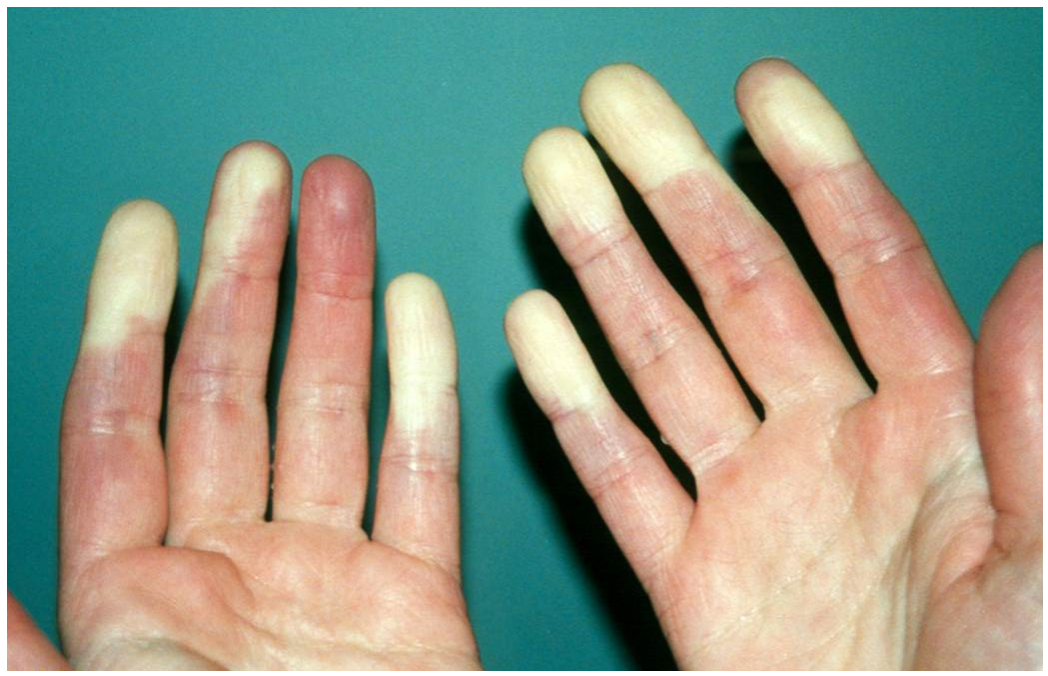

Typically there is a short history of Raynaud's phenomenon.

Denton CP, Khanna D. *Lancet*. 2017. doi:10.1016/S0140-6736(17)30933-9.

These images depict examples of some of the manifestations observed in patients with systemic sclerosis. This is for educational purposes only and should not be used as the basis for systematic assessment and follow-up. Patient clinical presentations may vary.

DIFFUSE CUTANEOUS SYSTEMIC SCLEROSIS

A subtype with extensive internal organ and skin involvement

Clinical presentation

Salt-and-pepper skin discoloration

Digital ulcers

Early distal skin thickening can progress to involve proximal extremities as well as the trunk.

- **Peak skin involvement occurs at 12–18 months**
- **Skin thickness may decrease late in the disease**

Digital ulcers may be present.

Denton CP, Khanna D. *Lancet*. 2017. doi:10.1016/S0140-6736(17)30933-9.
Pattanaik D, et al. *Front Immunol*. 2015;6:272. doi:10.3389/fimmu.2015.00272.

These images depict examples of some of the manifestations observed in patients with systemic sclerosis. This is for educational purposes only and should not be used as the basis for systematic assessment and follow-up. Patient clinical presentations may vary.

DIFFUSE CUTANEOUS SYSTEMIC SCLEROSIS

A subtype with extensive internal organ and skin involvement

Clinical presentation

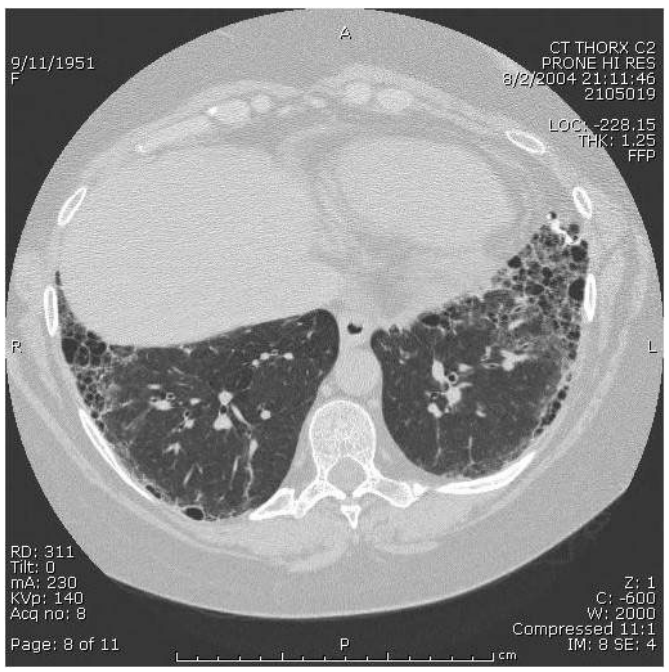

25%–30% of patients develop progressive interstitial lung disease.

Denton CP, Khanna D. *Lancet*. 2017. doi:10.1016/S0140-6736(17)30933-9.

These images depict examples of some of the manifestations observed in patients with systemic sclerosis. This is for educational purposes only and should not be used as the basis for systematic assessment and follow-up. Patient clinical presentations may vary.

DIFFUSE CUTANEOUS SYSTEMIC SCLEROSIS

A subtype with extensive internal organ and skin involvement

Clinical presentation

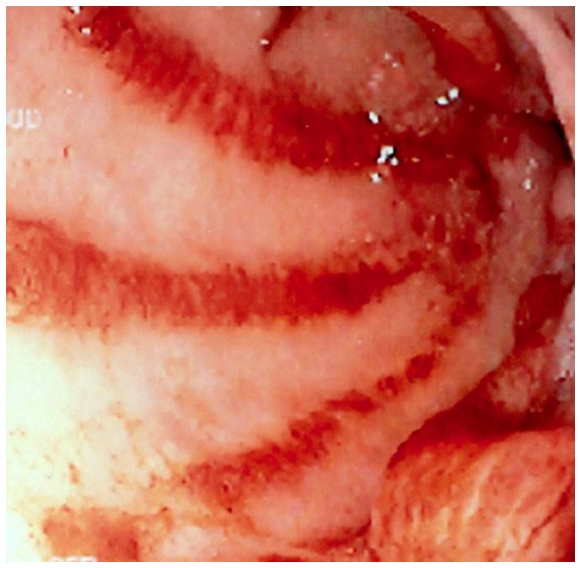

Early gastric antral vascular ectasia (watermelon stomach) may occur.

Denton CP, Khanna D. *Lancet*. 2017. doi:10.1016/S0140-6736(17)30933-9.
Parrado RH, et al. *Int J Rheumatol*. 2015;2015:762546.

These images depict examples of some of the manifestations observed in patients with systemic sclerosis. This is for educational purposes only and should not be used as the basis for systematic assessment and follow-up. Patient clinical presentations may vary.

DIFFUSE CUTANEOUS SYSTEMIC SCLEROSIS

A subtype with extensive internal organ and skin involvement

Clinical presentation

Gastrointestinal complications in the small and large intestine, including blind loop syndrome (small intestinal bacterial overgrowth), malabsorption syndrome, and intestinal pseudo-obstruction, are common.

Denton CP, Khanna D. *Lancet*. 2017. doi:10.1016/S0140-6736(17)30933-9.
Kumar S, et al. *Aliment Pharmacol Ther*. 2017;45(7):883-898.
Pattanaik D, et al. *Front Immunol*. 2015;6:272. doi:10.3389/fimmu.2015.00272.

These images depict examples of some of the manifestations observed in patients with systemic sclerosis. This is for educational purposes only and should not be used as the basis for systematic assessment and follow-up. Patient clinical presentations may vary.

DIFFUSE CUTANEOUS SYSTEMIC SCLEROSIS

A subtype with extensive internal organ and skin involvement



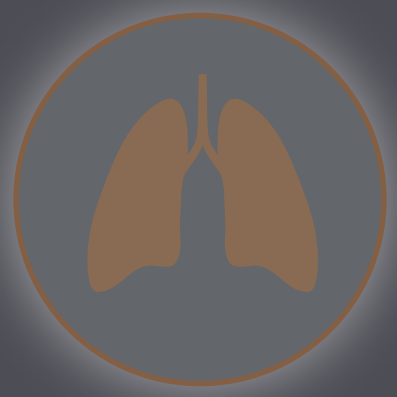

Autoantibody profile

Anti-Scl-70 (anti-DNA topoisomerase I) autoantibodies are associated with diffuse systemic sclerosis, progressive lung fibrosis, digital ulcers, and hand disability. Anti-RNA polymerase III autoantibodies are associated with diffuse systemic sclerosis, scleroderma renal crisis, and hand disability.

Denton CP, Khanna D. *Lancet*. 2017. doi:10.1016/S0140-6736(17)30933-9.
Gabrielli A, et al. *N Engl J Med*. 2009;360(19):1989-2003.

These images depict examples of some of the manifestations observed in patients with systemic sclerosis. This is for educational purposes only and should not be used as the basis for systematic assessment and follow-up. Patient clinical presentations may vary.

SYSTEMIC SCLEROSIS

A rare, progressive, immune-mediated disease

NOT JUST SKIN DEEP

These images depict examples of some of the manifestations observed in patients with systemic sclerosis. This is for educational purposes only and should not be used as the basis for systematic assessment and follow-up. Patient clinical presentations may vary.